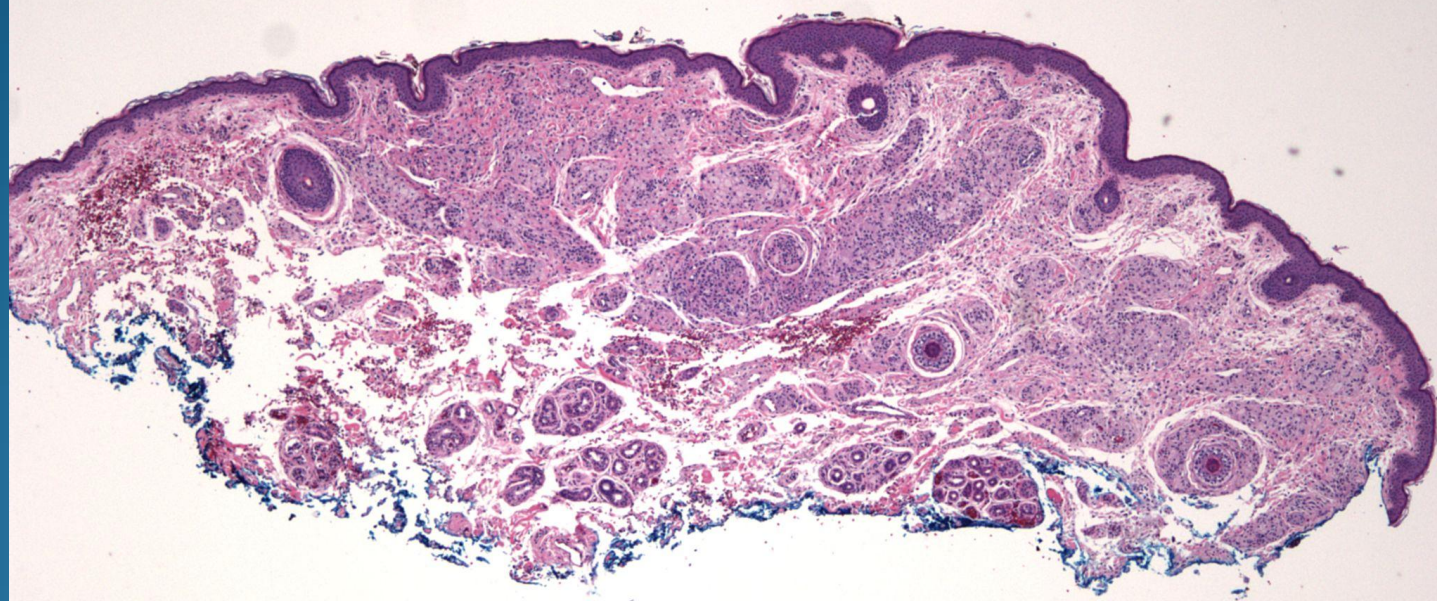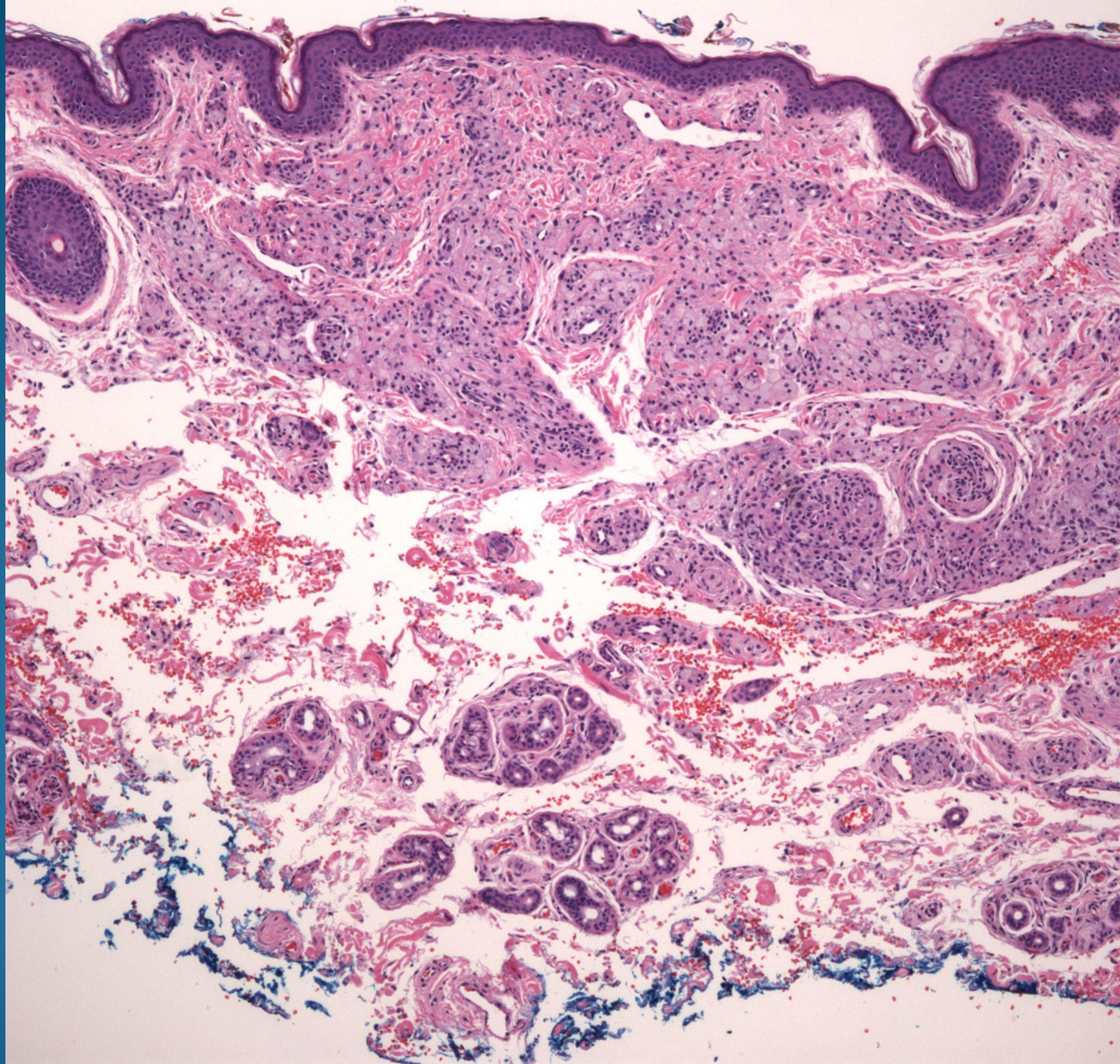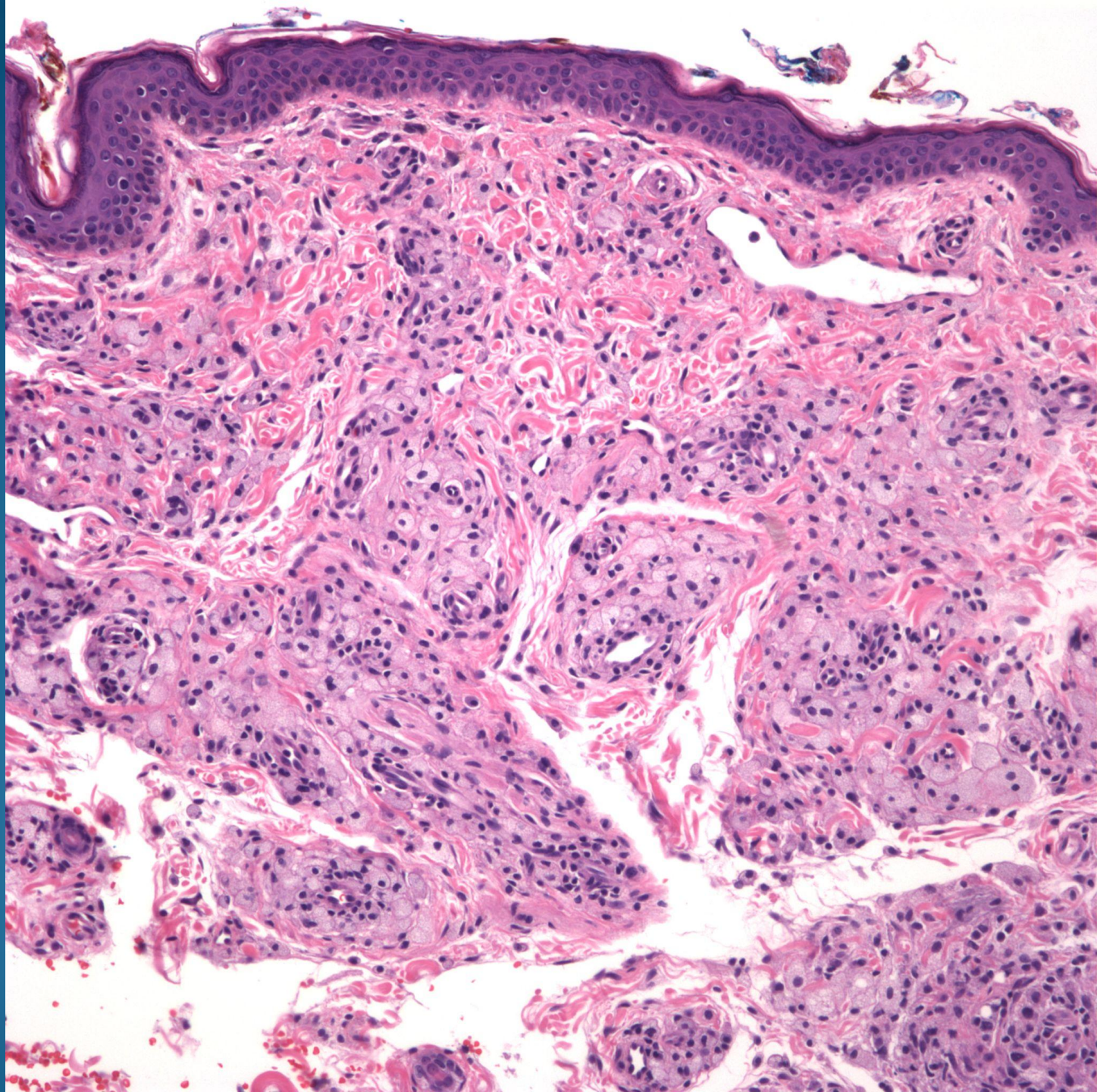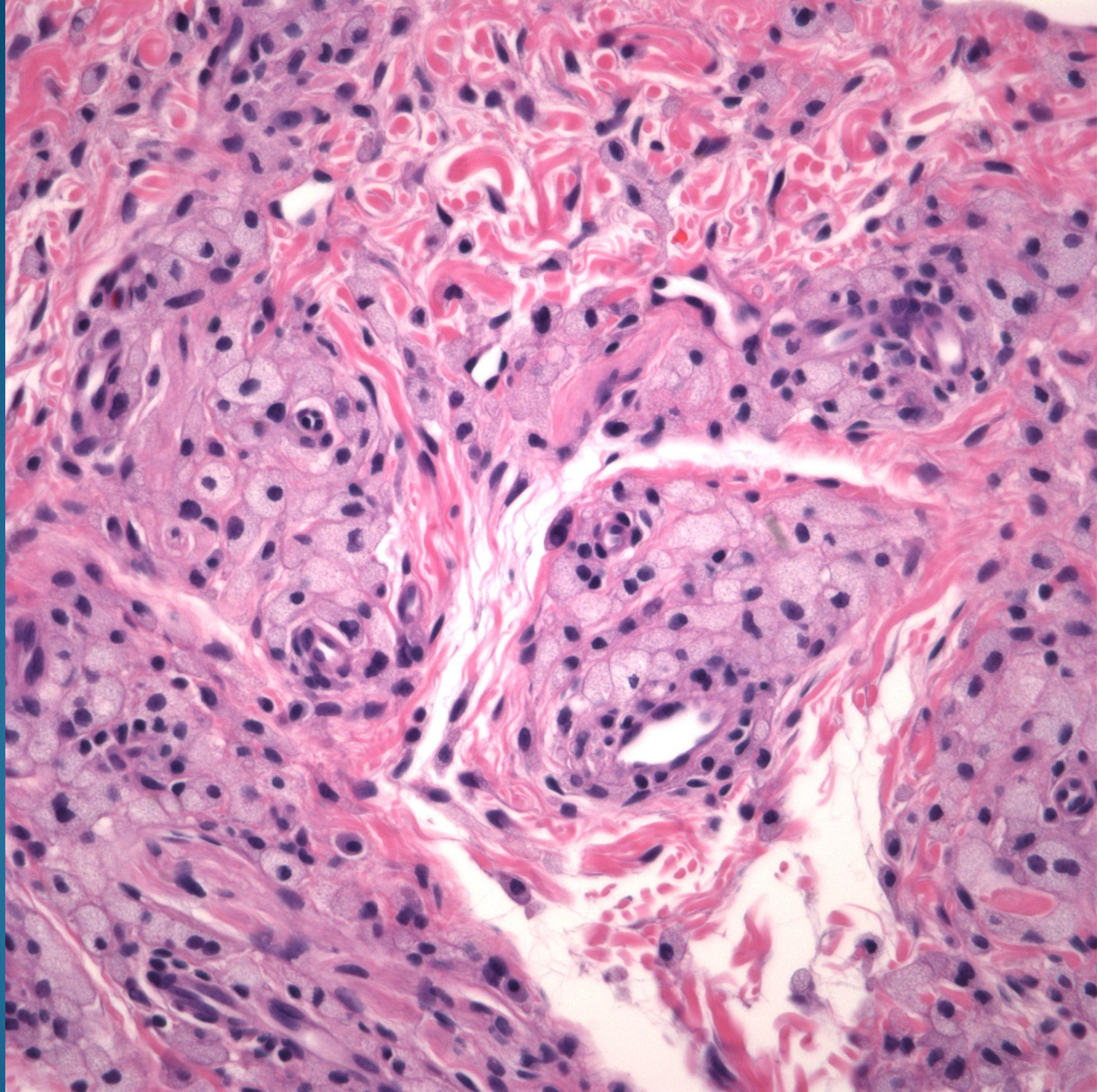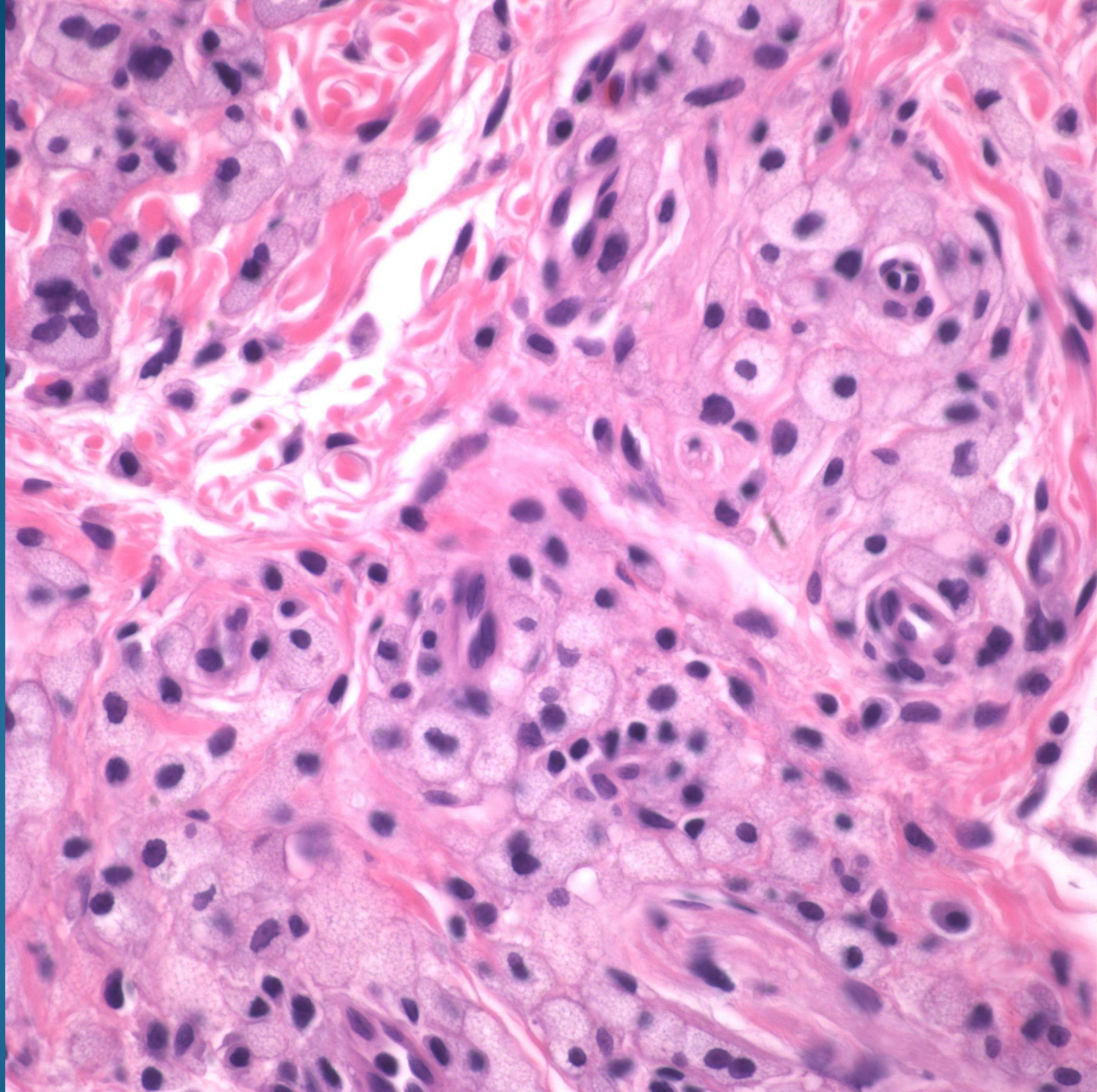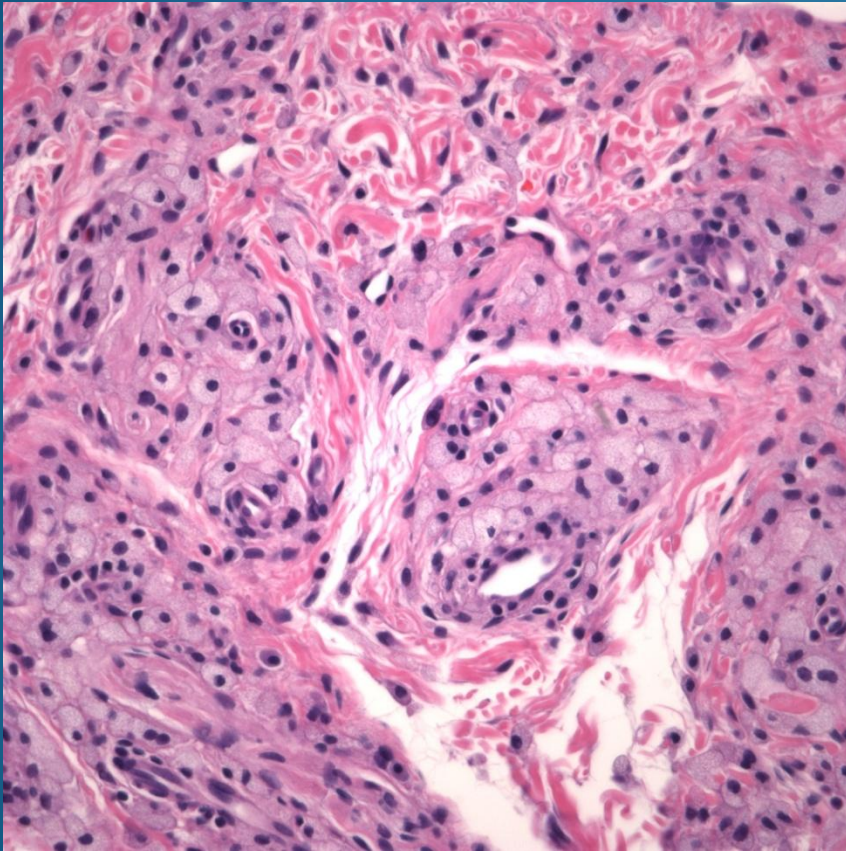


# Xanthelasma



# Pearls



- Low power architecture of melanocytic nevus
- Diffuse and nodular collection of foamy histiocytes
- No cytologic atypia
- Usually minimal chronic inflammation
- May need IHC-CD68+ to confirm